

## Grading System for Gunshot Injuries to the Femoral Diaphysis in Civilians

*William T. Long, MD; Wayne Chang, MD; and Earl W. Brien, MD*

One hundred patients had surgical treatment for a gunshot injury to the femur at the authors' hospital. Each injury was classified (Grade 1–3) based on clinical and radiographic signs of deep soft tissue necrosis. All patients were followed up for a minimum of 6 months (average, 18 months; range, 6 months–72 months). Grade 1 injuries are defined by small entry and exit wounds (< 2 cm) and the absence of high-energy characteristics on plain radiographs. Grade 2 gunshot injuries have small wounds (< 5 cm) and radiographic evidence of a high-energy injury. Grade 3 gunshot injuries are diagnosed by physical examination whenever necrotic muscle is present at the fracture site. Radiographs show extensive superficial and deep soft tissue disruption and segmental bone destruction. Seventy-nine patients with Grade 1 fractures had intramedullary nailing without wound exploration; all fractures united without infection. Seven patients with Grade 2 injuries had wound exploration; a necrotic cavity was discovered in five patients and three (43%) patients had deep infection develop. Fourteen patients with Grade 3 injuries had one or more debridements followed by skeletal stabilization, and seven patients (50%) had deep infection develop. Important decisions regarding wound debridement and fracture stabi-

**lization are determined by examination of the wound and radiographs, and not by determining muzzle velocity.**

An orthopaedic surgeon practicing in the United States rarely will encounter a patient with a femur fracture caused by a gunshot. Less than ½ of cases reported each year present to urban trauma centers, whereas the remainder present to community hospitals with little or no experience treating these injuries. Guidelines used today for the treatment of gunshot injuries in civilians are based on the velocity of the projectile ( $KE = \frac{1}{2}mv^2$ ).<sup>3,8,29</sup> Weapons are classified according to muzzle velocity as low-velocity (< 600 m/s, most handguns) and high-velocity (> 600 m/s, most military rifles). In the military ballistics laboratory, the zone of soft tissue destruction expands as muzzle velocity increases.<sup>10–13</sup> Low-velocity gunshot wounds are classified as Gustilo Type I injuries and high-velocity gunshot wounds are classified as Gustilo Type III injuries.<sup>15,16</sup> The recommended treatment includes immediate nailing of Type I injuries.<sup>14</sup> Debridement, broad-spectrum antibiotics, and delayed nailing are recommended for Type III injuries.<sup>23</sup> Leffers and Chandler<sup>19</sup> described intermediate-energy gunshot injuries to the tibia (680–1627 N-m). These injuries were characterized by highly comminuted fractures and they had complication rates similar to

From the Dr. Martin Luther King/Charles Drew Medical Center; Los Angeles, CA.

Reprint requests to William T. Long, MD, Dr. Martin Luther King/Charles Drew Medical Center, 12021 S. Wilmington #3024, Los Angeles, CA 90059. Phone: 310-668-4534; Fax: 310-223-0733; E-mail: sputilong@aol.com.

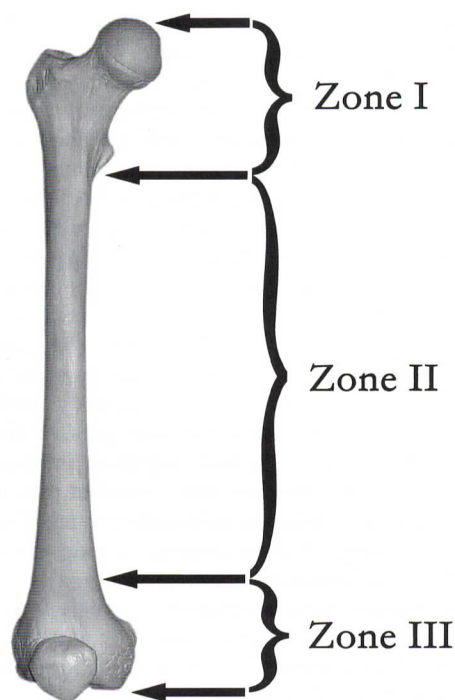
DOI: 10.1097/01.blo.0000052644.74302.3a

high-velocity gunshot injuries. Knowledge of multiple factors is necessary for an adequate understanding of wound production. Factors such as bullet caliber, mass, yaw, shape, impact velocity, and target tissue density all modify the severity of the wound formed.<sup>6,18,23,26</sup> A civilian physician who treats these emergencies has little information regarding these bullet characteristics and no reliable method to determine muzzle velocity. A classification system is described that provides guidelines for emergency surgical treatment of patients who sustain a gunshot injury to the femoral diaphysis.

### MATERIALS AND METHODS

One hundred patients had surgical treatment for a gunshot injury to the femoral diaphysis at the authors' hospital between January 1993 and December 1996. The study group included every patient with a gunshot injury to the femoral diaphysis who was treated surgically. The femur is divided into three zones to emphasize the risk of joint violation (Fig 1). Zone I (hip at risk) includes fractures of the femur proximal to the distal end of the lesser trochanter. Zone II (the femoral diaphysis) is defined as a fracture distal to the distal end of the lesser trochanter and proximal to the distal metaphyseal diaphyseal junction. Zone III (knee at risk) includes fractures below the distal metaphyseal diaphyseal junction. Every patient in this study had a Zone II gunshot fracture. Patients ranged in age from 18 to 58 years (mean, 36 years). There were 94 men and six women. Followup was from 6 to 72 months (mean, 18 months).

Seventy-three patients who sustained a gunshot wound from January 1993 to December 1995 were studied retrospectively. Twenty-seven patients injured from January 1996 to December 1996 were studied prospectively, and data collection began when these patients presented to the orthopaedic service. All patients had followup until the fracture united. The medical history and clinical information were obtained by reviewing medical records and radiographs. Missing or incomplete data were obtained by telephone interview or by examination in the orthopaedic clinic at the authors' institution. In addition to routine information, evaluation of gunshot injuries included a description of the weapon as a handgun, rifle, or assault weapon. Pa-



**Fig 1.** Zone I (hip at risk) includes fractures of the femur proximal to the lesser trochanter. Zone II (the femoral diaphysis) is defined as a fracture distal to the distal end of the lesser trochanter and proximal to the distal metaphyseal diaphyseal junction. Zone III (knee at risk) includes fractures below the distal metaphyseal diaphyseal junction. Every patient in the current study had a Zone II gunshot fracture.

tients with shotgun injuries and injuries in Zones I and III were excluded from the study. Physical examination includes the basic principles of advanced trauma life support. A complete evaluation of gunshot victims includes turning the patient to examine the gluteal folds and crease and the popliteal space. Each wound is identified as an entry or exit wound. The size, location, and appearance of each wound are recorded using a diagram.

Standard radiographs include an anteroposterior (AP) view of the pelvis and AP and lateral views of the femur and knee. A systematic evaluation of the soft tissues, the bone, and the bullet will provide valuable signs to identify the fracture as low-energy or high-energy. The superficial soft tissue shadows are examined for defects in the skin and subcutaneous tissue. The deep tissues are examined



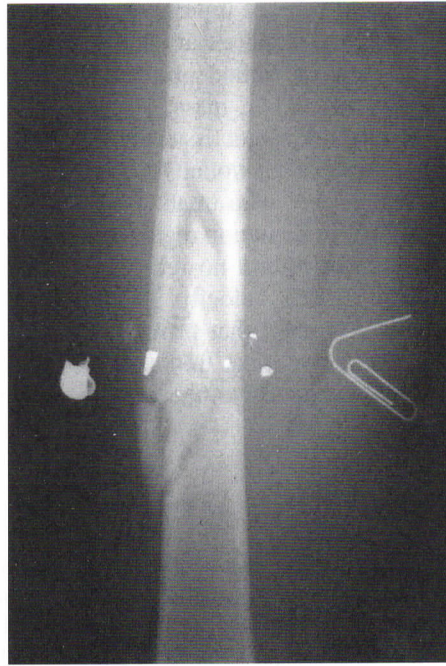for disruption of muscle and infiltration with air, bullet, and bone debris. The bone is evaluated by counting the number of small ( $< 3$  cm) and large fracture fragments. A fracture with greater than 10 large fragments and greater than 10 small fragments is described as severely comminuted. Segmental bone destruction describes a 7-cm area of bone that cannot be reconstructed by all of the fragments present on the radiograph. A retained bullet is evaluated by estimating the caliber and recording the size, number, and distribution of metal fragments. Bullet fragments combined with bone particles and air provides objective evidence regarding the area of tissue violated by the gunshot wound.

The radiographs of a low-energy gunshot show an intact soft tissue shadow. Small air infiltrates may be present along the bullet tract but they are not dispersed widely throughout the tissues. Common low-energy fracture patterns include oblique fractures with several large fragments and several small cortical fragments around the point of bullet impact. Segmental bone destruction is not characteristic of low-energy gunshot injuries of the femur. The low-energy bullet appears as a solid projectile, or it may be broken into several small fragments along a narrow tract (Fig 2).

The radiographic signs that are most important in identifying a Grade 3 gunshot injury are found in the soft tissue. A large defect in the shadow that outlines skin and subcutaneous tissue represents an entry or exit wound. The muscle shadow is swollen and irregular. A mixture of bone fragments, bullet fragments, and air penetrate a wide area within the thigh. Severe comminution and segmental bone destruction are fracture patterns that characterize a Grade 3 gunshot injury (Fig 3).

Each gunshot is classified as Grade 1, 2, or 3, based on examination of the wound and the radiographic findings (Table 1). Grade 1 is a low-energy injury with small ( $< 2$  cm) entrance and exit wounds. No necrotic muscle is identified during wound examination. Radiographs show intact skin and subcutaneous tissue, and no muscle disruption or segmental bone destruction.

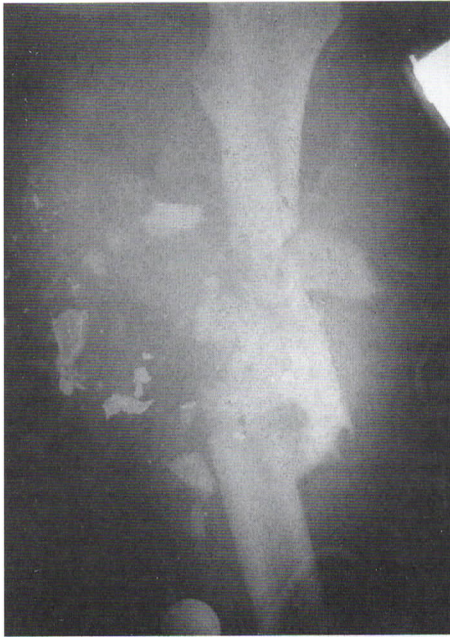A gunshot injury is classified as Grade 2 when the entrance and exit wounds are small ( $> 5$  cm); however, radiographs show ominous signs of deep tissue destruction (Fig 4). Severe comminution of the diaphysis and segmental bone destruction call attention to these injuries. Evaluation of the soft tissues reveals infiltration of the muscles with air, bullet, and bone debris.



**Fig 2.** Radiographs of a low-energy gunshot show an intact soft tissue shadow. Scant air infiltration is present along the bullet tract. The diaphysis is comminuted and there are several large and small fragments. The projectile consists of a solid bullet plus a few small fragments along a narrow wound channel.

A Grade 3 gunshot can be defined by the size and appearance of the entry or exit wound or by radiographs alone. A patient with a large ( $> 5$  cm) devitalized entry or exit wound is classified as having a Grade 3 injury. A patient with a smaller wound (2–5 cm) also is classified as having a Grade 3 injury whenever devitalized muscle is identified in the wound. The radiographs usually show severe comminution or segmental bone destruction. Air, bullet and bone fragments provide images that approximate the size of the wound cavity. To diagnose a Grade 3 injury solely on the basis of a radiograph, the image must show a large defect in the skin and subcutaneous tissue or clear evidence of devitalized muscle at the fracture site.

All patients are given intravenous antibiotics and tetanus prophylaxis in the emergency room. Patients classified as having a Grade 1 injury are treated with Ancef (SmithKline Beecham, Philadelphia, PA) and



**Fig 3.** A high-energy gunshot injury is identified radiographically by disruption of the soft tissue. The thigh muscles are swollen markedly and infiltrated with air, bone, and metal debris along a wide area. Segmental bone destruction is present with numerous small and large fragments. The bullet has disintegrated and dispersed throughout a wide area of muscle and subcutaneous tissue. This patient had a small entry wound, no exit wound, and initially was classified as having a Grade 2 injury. Wound exploration confirmed the presence of a large cavity with devitalized muscle.

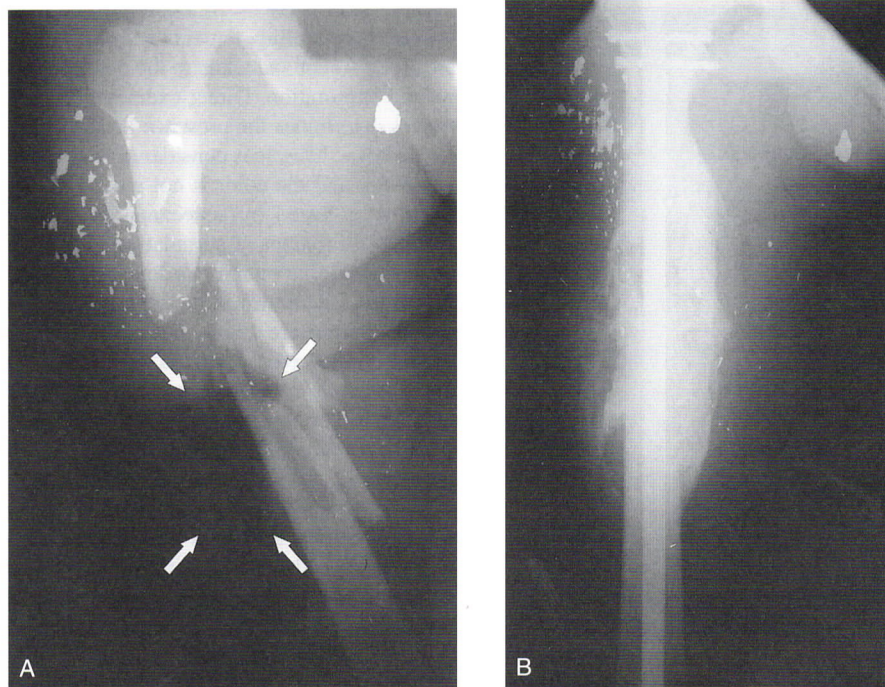
immediate or early (< 48 hours) closed reamed intramedullary nailing. Patients with a Grade 2 injury are given Ancef and taken to the operating room for wound exploration. Direct examination of the soft tissues determines the presence or absence of muscle necrosis. Muscle is considered viable if it bleeds when cut, and the color is not pale or dusky. Contractility is tested by squeezing the muscle belly lightly with forceps or stimulating it with a cautery tip. Intramedullary nailing is done immediately after the wound exploration if the surgeon determines that the soft tissues are viable. Operative skin incisions are sutured closed if doing so does not produce undue tension at the skin edges. The bullet entry and exit wounds are not sutured closed.

When a Grade 2 injury is explored and devitalized muscle is discovered, the patient is treated according to the protocol for patients with high-energy Grade 3 injuries. This protocol includes tetanus prophylaxis, broad-spectrum intravenous antibiotics, and excision of all nonviable skin, subcutaneous tissue, fascia, muscle, and periosteum. Free-floating fragments of the soft tissue, bone, and bullet are removed (Fig 5). Periosteum with attached bone fragments are preserved. During the first debridement, it often is difficult to distinguish living from dead muscle, especially in large wounds with extensive cavitation. When the viability of muscle is in doubt, or when bone cannot be covered with healthy living tissue, the skin edges are approximated over drains or sterile gauze packing, and the fracture is stabilized by skeletal traction or external fixation. The patient is scheduled to return the operating room in 2 to 3 days for wound exploration and debridement. Internal fixation is done when all necrotic tissue has been

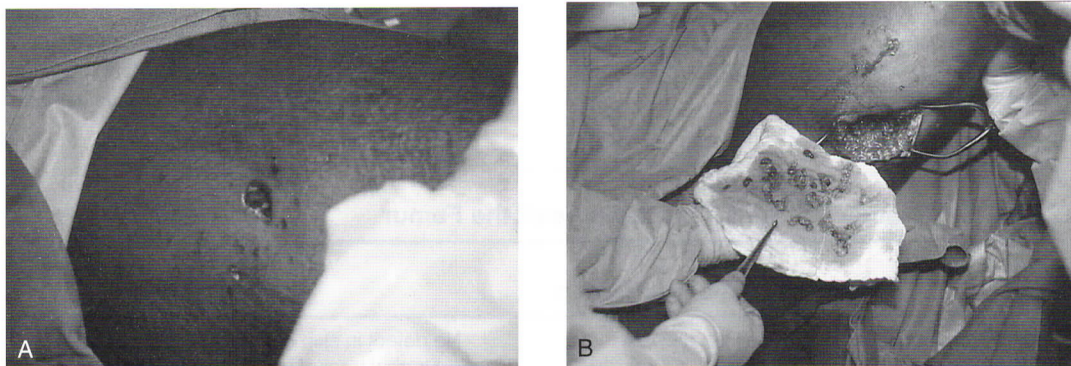
**TABLE 1. Grades for Gunshot Fractures of the Femur**

Gunshot Grade	Wound size and appearance	Radiographs
Grade 1	< 2 cm, no devitalized muscle	No defect in skin or subcutaneous tissue. Narrow tract of metal, bone and air through muscle. Comminution with several large and small fragments.
Grade 2	<5 cm, no devitalized muscle	Muscle swelling and a wide area of infiltration with metal, bone and air. Severe comminution or segmental bone loss.
Grade 3	>5 cm or 2-5 cm with devitalized muscle	Same as Grade 2, plus a defect in the skin and subcutaneous tissue.





**Fig 4A–B.** (A) A radiograph shows a patient with a 5-cm entry wound and necrotic muscle. The radiographs of this Grade 3 injury show a wide area of muscle infiltrated by bullet and bone fragments. The arrows indicate a large pocket of air where the soft tissues have been displaced or destroyed. (B) Gunshot fractures to the femur typically heal rapidly with abundant callus. Despite severe comminution, the bone fragments maintain their blood supply and most of the periosteum remains viable.



**Fig 5A–B.** (A) This patient had an injury that was classified as Grade 2 because the entry and exit wounds were small but the radiographs showed signs of a high-energy injury. The thigh had a 1-cm entry wound and a 2-cm exit wound and numerous small exit wounds caused by exiting fragments of bullet and bone. (B) Exploration of the exit wound revealed a large deep cavity filled with necrotic subcutaneous tissue, muscle fragments, and pieces of bullet and bone. This patient's injury shows that high-energy gunshot wounds do not always have large entry and exit wounds.

removed and when the bone is covered with healthy soft tissue. No patient in this study had soft tissue reconstruction with a muscle flap. High-energy fractures with extensive soft tissue wounds initially were stabilized in traction or with external fixation. In wounds that became infected plate and screws fixation was done when the infection was resolved.

## RESULTS

Thirty-four of 100 patients (34%) were able to provide a description of the weapon as a handgun, rifle, or assault weapon whereas the remaining patients could not describe the weapon responsible for the injury. Eighty-five patients had entry wounds and 15 had entry and exit wounds. All 79 patients with a Grade 1 injury had a 1- to 2-cm (small) wound. Two patients with Grade 2 injuries had a small (< 2 cm) wound, and five patients had medium wounds (< 5 cm). Twelve patients with a Grade 3 gunshot injury had large wounds (> 5 cm) and two patients had medium wounds with devitalized muscle visible in the wound. Exit wounds were present in five patients with Grade 1 injuries, in two patients with Grade 2 injuries, and in eight patients with Grade 3 injuries. Four of the patients with Grade 3 injuries and one of the patients with a Grade 2 gunshot injury had multiple exit wounds caused by secondary missiles, bone, and metal fragments created when a high-energy bullet strikes the bone.

Seventy-nine patients were classified as having Grade 1 injuries; none of these patients had a deep infection. Seven patients were classified as having Grade 2 injuries; all of the patients had wound exploration and deep tissue necrosis was seen in five patients. Three patients (43%) with a Grade 2 injury had a deep infection develop. Two of these infections occurred in patients who had two or more debridements followed by intramedullary nailing. The third Grade 2 infection occurred in a patient who was treated with one-stage debridement and intramedullary nailing.

Fourteen patients had a Grade 3 injury and seven (50%) had a deep infection develop. Nine patients with Grade 3 femur fractures

were treated with multiple debridements. Definitive treatment was external fixation in two patients, plate fixation in two patients, and an intramedullary nail in five patients. There were four deep infections in the nine patients with Grade 3 injuries who were treated with multiple debridements. Two patients had large necrotic wounds that continued to drain despite multiple debridements and traction. The wound drainage resolved and both fractures united after stabilization using external fixation. A third patient with an infected fracture was treated with multiple debridements and an external fixator. The fracture had no evidence of healing 5 months after the injury. The soft tissue wound was closed and dry when the fracture fixation was converted to a plate and screws. Four months after the injury the fracture was united. A fourth patient was diagnosed with having an infection after two debridements and intramedullary nailing. The patient had constant thigh pain, a fever, and persistent serosanguineous drainage from the bullet entry site. After the infection was diagnosed, the patient had three additional debridements with the nail in place and a 6-week course of intravenous antibiotics. The fracture healed and the nail was removed 6 months after the injury.

Five patients with Grade 3 gunshot wounds had one-stage debridement and internal fixation; three of these patients had a deep infection develop. One of the infections was diagnosed after intramedullary nailing in a patient who had continued pain, serosanguineous drainage, fever, and positive intraoperative wound cultures. The patient was treated with multiple debridements and a 6-week course of intravenous antibiotics. Eight months after the injury the fracture was united but the patient would not consent to another operation to have the nail removed. At 5 years followup, the patient continued to have intermittent serosanguineous drainage from the incision site. The second patient was diagnosed with infection 36 months after one-stage nailing of a segmental femur fracture. The patient presented with constant pain and drainage from the me-



dial side of the proximal thigh. After the nail was removed cultures confirmed infection with *Staphylococcus aureus*. The wound drainage and thigh pain resolved after a 6-week course of intravenous antibiotics. The third infection occurred in a patient who had debridement and immediate plate fixation of the femur after reconstruction of the superficial femoral artery near the adductor hiatus. The patient had a transfusion with 58 units of blood products within 48 hours of sustaining multiple gunshot injuries. The patient had persistent serosanguineous drainage from the thigh incision but the fracture united 3 months after the injury. The plate was removed 7 months after the injury; however, 4 years after hardware removal the patient continued to have intermittent episodes of drainage from the incision site.

## DISCUSSION

Historically, gunshot wounds have been classified as low-velocity (< 600 m/s) or high-velocity (> 600 m/s). Orthopaedic surgeons have long observed that high-velocity bullets produce larger wounds and are associated with more infections than injuries caused by low-velocity bullets. Experiments done in ballistics laboratories have established the correlation between bullet velocity and soft tissue necrosis.<sup>1,17</sup> When the patient describes the weapon as a rifle or an assault weapon, this should alert the physician to the potential presence of deep, devitalized tissue. Sixty-six percent of the patients in the current study could not describe the weapon that caused the femur fracture. Billings et al<sup>5</sup> reviewed 44 civilians with gunshot injuries to the upper and lower extremities and found that information regarding the weapon that caused the injury was recorded only 47% of the time. A classification system for gunshot injuries in civilians should not rely on a description of the weapon because more than 1/2 of the patients cannot identify the weapon and in many cases the description is unreliable. Knowledge of the weapon type does not always equal knowledge of muzzle velocity. Muzzle velocity may

be compromised by poor weapon maintenance and old ammunition. After a bullet leaves the muzzle, it can ricochet or pass through an object before striking the victim. A high-velocity weapon can result in the production of a low-energy wound.

More serious consequences occur when a low-velocity weapon causes deep tissue destruction that is characteristic of a high-velocity injury. In 1988, Fackler<sup>12</sup> used wound profile experiments to challenge the widespread claims that all high-velocity projectiles cause wounds that must be treated by extensive excision of tissue, whereas low-velocity bullet wounds never need debridement. The wound profile data suggested that low-velocity bullets can cause large permanent cavities because of the projectile-tissue interaction. The bullet motion, shape, and fragmentation pattern have a marked impact on tissue disruption.<sup>3</sup> Target tissue density plays an important role in wound channel production, because more elastic tissues such as skin and muscle will stretch and sustain relatively less damage than a nonelastic tissue such as the liver.

When the treating physician makes a decision regarding treatment without knowing the type of weapon, the appearance of the wound dictates the course of treatment. Patients with large devitalized wounds are treated according to the protocol for patients with high-energy open femur fractures. Patients with small entry and exit wounds are classified as having low-energy injuries and treatment includes early nailing without debridement. Experience with more than 2000 gunshot injuries each year at the authors' institution had brought attention to a significant number of patients who have small bullet wounds associated with radiographic signs of high-energy fractures. In these cases, the bullet pierces the skin leaving a small entry wound. After penetrating the skin the projectile can flatten, begin to tumble, or break apart. Destructive energy is released into the deep tissues creating a large permanent cavity. Grade 2 injuries are identified by high-energy radiographic features. Damage inflicted to muscle is related to the passage of

the projectile through tissue, a secondary shock wave, and temporary cavitation. Negative pressure draws air and contamination into the affected limb and air infiltrates seen on the radiographs help to show the zone of tissue disruption. The large wound cavity also is shown by the distribution of bullet and bone fragments throughout the soft tissues. These radiographic signs clearly show areas of tissue that were affected by the gunshot wound. Direct examination of the tissues is the most effective method to determine their viability.

Adequate (6 to 72 months) followup was available to determine the rate of fracture union (100%) and the incidence of deep wound infection (10%) in the 100 patients included in the current study. There were no deep infections and no wound complications in 79 consecutive patients with Grade 1 injuries. Wiss et al<sup>28</sup> observed no infections in 56 patients treated with intramedullary nailing of the femur for fractures caused by low-velocity gunshots. The observed low risk of infection in this and other studies encourages continued treatment of Grade 1 gunshot injuries to the femur as closed fracture equivalents.<sup>7,8,14,20,22,24</sup>

There were 10 deep infections in the 100 patients studied. All of the infections occurred in patients who had high-energy characteristics on plain radiographs. Nine of the patients with infected femurs had a large necrotic cavity at the time of the initial wound debridement and the tenth patient had an ipsilateral superficial femoral artery transection. The key radiographic findings to determine wound grade are found in the soft tissues.<sup>26,28</sup>

There previously have been no clear guidelines to evaluate radiographic features of the soft tissues in gunshot injuries. No one radiographic finding defines a high-energy gunshot wound. Comminution is common in low-velocity gunshot fractures of the femur and should not be used alone as the criteria to diagnose a high-velocity gunshot wound. When considered together, the combination of air, bullet, and bone particles provides an excellent radiographic image of a wound cavity or

tract. Seven patients with unremarkable wounds had wound exploration because the radiographs showed signs of deep tissue disruption. Two patients had wound exploration, the muscles appeared healthy and viable, and there was no cavity. When this occurred, the patients had one-stage wound exploration and intramedullary nailing. These two fractures healed without any complications. In five other patients with Grade 2 injuries, the large devitalized cavity was found during wound exploration. In each of these cases, surgical exploration provided early removal of devitalized, contaminated tissue. This approach is consistent with the accepted principals of treatment of other open femur fractures.<sup>4,9,25,27</sup>

In the current series, the Grade 3 gunshot injuries were not difficult to diagnose because devitalized tissue was apparent by direct examination of the wound. The description of the wound appearance and radiographic signs associated with high-energy injuries have been consistent among previous authors. The current classification provides specific criteria by which one can make the diagnosis of a high-energy injury based solely on radiographs. Treatment recommendations are based on principles of open fracture treatment for other contaminated high-energy wounds. Excision of the devitalized tissue, broad-spectrum intravenous antibiotics, and repeated debridement is recommended. Internal fixation should be done when the wound is free of necrotic tissue, and the fracture is covered with healthy soft tissue.

Assessment of penetrating trauma to the extremities has its foundation in history, physical examination, plain radiographs, and surgical wound exploration. The femur is a large, well-vascularized bone covered with thick layers of muscle. Gunshot injuries to other areas such as the sole of the foot and the spine have unique anatomic considerations that are important in surgical decision-making.<sup>2,21</sup> The correlation between wound appearance, radiographic findings, and infection found in the femoral diaphysis may not apply to other anatomic regions. Additional research is indi-



cated to determine the role of this classification system in fractures in other extremities.

## References

1. Anania WC, Rosen RC, Giuffre AM: Gunshot wounds to the lower extremity: Principles and treatment. *J Foot Surg* 26:228-232, 1987.
2. Ashby ME: Low-velocity gunshot wounds involving the knee joint: Surgical management. *J Bone Joint Surg* 56A:1047-1053, 1974.
3. Barach E, Tomlanovich M, Nowak R: Ballistics: A pathophysiologic examination of the wounding mechanisms of firearms: Part I. *J Trauma* 26:225-235, 1986.
4. Behrman SW, Fabian TC, Kudsk M, Taylor JC: Improved outcome with femur fractures: Early vs. delayed fixation. *J Trauma* 30:792-798, 1990.
5. Billings JB, Zimmerman MC, Aurori B, Parsons JR, Swan KG: Gunshot wounds to the extremities: Experience of a level I trauma center. *Orthop Rev* 10:519-524, 1991.
6. Brav E, Jeffress VH: Modified intramedullary nailing in recent gunshot fractures of the femoral shaft. *J Bone Joint Surg* 35A:141-152, 1953.
7. Brien EW, Long WT, Serocki JH: Management of gunshot wounds to the tibia. *Orthop Clin North Am* 26:133-138, 1995.
8. Brien WW, Kuschner SH, Brien EW, Wiss DA: The management of gunshot wounds to the femur. *Orthop Clin North Am* 26:133-138, 1995.
9. Brumback RJ, Ellison Jr S, Poka A, et al: Intramedullary nailing of open fractures of the femoral shaft. *J Bone Joint Surg* 71A:1324-1330, 1989.
10. Carr CR, Turnispeed D: Experiences with intramedullary fixation of compound femoral fractures in war wounds. *J Bone Joint Surg* 35A:153-171, 1953.
11. DeMuth Jr WE, Smith JM: High-velocity bullet wounds of muscle and bone: The basis of rational early treatment. *J Trauma* 6:744-755, 1966.
12. Fackler ML: Wound ballistics: A review of common misconceptions. *JAMA* 259:2730-2736, 1988.
13. Finck PA: Ballistic and forensic pathologic aspects of missile wounds: Conversion between anglo-American and metric-system units. *Mil Med* 130:545-569, 1965.
14. Geissler WB, Teasdale RD, Tomasin JD, Hughes JL: Management of low velocity gunshot-induced fractures. *J Orthop Trauma* 4:39-41, 1990.
15. Gustilo RB, Anderson JT: Prevention of infection in the treatment of one thousand and twenty-five open fractures of the long bones: Retrospective and prospective analysis. *J Bone Joint Surg* 58A:453-458, 1976.
16. Gustilo RB, Mendoza RM, Williams DN: Problems in the management of type III (severe) open fractures: A new classification of type III open fractures. *J Trauma* 24:742-746, 1984.
17. Howland Jr WS, Ritchey SJ: Gunshot fractures in civilian practice. *J Bone Joint Surg* 53A:47-55, 1971.
18. King KF: Orthopaedic aspects of war wounds in South Vietnam. *J Bone Joint Surg* 51B:112-117, 1969.
19. Leffers D, Chandler RW: Tibial fractures associated with civilian gunshot injuries. *J Trauma* 25:1059-1064, 1985.
20. Levy AS, Wetzler MJ, Guttman G, Covall DJ, Fink B: Treating gunshot femoral shaft fractures with immediate reamed intramedullary nailing. *Orthop Rev* 7:805-809, 1993.
21. Long WT, Brien EW, Boucree Jr JB, Filler B, Stark HH: Management of civilian gunshot injuries to the hip. *Orthop Clin North Am* 26:123-131, 1995.
22. Marcus NA, Blair WF, Shuck JM, Omer Jr GE: Low-velocity gunshot wounds to extremities. *J Trauma* 20:1061-1064, 1980.
23. Mendelson JA: The relationship between mechanisms of wounding and principles of treatment of missile wounds. *J Trauma* 31:1181-1202, 1991.
24. Molinari RW, Yang EC, Strauss E, Einhorn TA: Timing of internal fixation of low velocity extremity gunshot fractures. *Contemp Orthop* 29:335-340, 1994.
25. Sanders R, Swionkowski M, Nunley J, Spiegel: The management of fractures with soft-tissue disruptions. *J Bone Joint Surg* 75A:778-789, 1993.
26. Smith HW, Wheatley KK: Biomechanics of femur fractures secondary to gunshot wounds. *J Trauma* 24:970-977, 1984.
27. Winkquist RA, Hansen Jr S: Comminuted fractures of the femoral shaft treated by intramedullary nailing. *Orthop Clin North Am* 11:633-648, 1980.
28. Wiss DA, Brien WW, Becker V: Interlocking nailing for the treatment of femoral fractures due to gunshot wounds. *J Bone Joint Surg* 73A:598-606, 1991.
29. Woloszyn JT, Uitvlugt GM, Castle ME: Management of civilian gunshot fractures of the extremities. *Clin Orthop* 226:247-251, 1988.